



# ACTAS Derma-Sifiliográficas

Full English text available at  
[www.actasdermo.org](http://www.actasdermo.org)



## PRACTICAL DERMATOLOGY

# Follicular Unit Extraction for Hair Transplantation: An Update<sup>☆</sup>



F. Jiménez-Acosta,\* I. Ponce-Rodríguez

Clinica Mediteknia de Dermatología y Trasplante Capilar, Las Palmas de Gran Canaria, Spain

Received 14 August 2016; accepted 24 February 2017  
Available online 11 June 2017

### KEYWORDS

Follicular unit  
extraction;  
Hair transplant;  
Follicular unit hair  
transplantation

**Abstract** Follicular unit extraction (FUE) is a hair transplantation technique that uses small punches (0.8-1 mm in diameter) to extract the follicular units (FUs). Though initially the technique was not widely accepted because of the difficulty of extracting intact follicular units with such small punches, it has since gained in popularity due mainly to rising patient demand, the availability of better instrumentation and greater surgical skill acquired from experience. It is now a recognised alternative to follicular unit transplantation (FUT), a technique based on harvesting the FUs from a strip of tissue. Among the advantages of FUE are less post-procedural discomfort in the donor zone and the barely visible scarring from the punches. However, FUE is a more laborious, time-consuming procedure that involves a long learning curve for the surgeon. © 2017 Elsevier España, S.L.U. and AEDV. All rights reserved.

### PALABRAS CLAVE

Extracción de  
unidades foliculares;  
Trasplante de pelo;  
Trasplante de  
unidades foliculares

### Actualización del método *Follicular Unit Extraction* (FUE) del trasplante de pelo

**Resumen** La *follicular unit extraction* (FUE) es una técnica de trasplante capilar que utiliza punches de pequeño diámetro (0,8-1 mm) para extraer las unidades foliculares. Aunque en sus primeros años tuvo escasa aceptación debido a la dificultad en extraer unidades foliculares intactas con un punch tan pequeño, la FUE se ha popularizado y es ya una alternativa a la técnica clásica de la tira (FUT). Entre los motivos, la cada vez mayor demanda por parte de los pacientes y la mayor habilidad de los cirujanos en las extracciones al contar con mejor instrumental y más experiencia. Entre las ventajas de la FUE destaca la reducción de molestias postoperatorias en la zona donante y el aspecto muy poco visible de las cicatrices puntiformes residuales. Sin embargo, la FUE requiere una mayor laboriosidad, aumentando el tiempo operatorio, y una larga curva de aprendizaje por parte del cirujano.

© 2017 Elsevier España, S.L.U. y AEDV. Todos los derechos reservados.

<sup>☆</sup> Please cite this article as: Jiménez-Acosta F, Ponce-Rodríguez I. Actualización del método *Follicular Unit Extraction* (FUE) del trasplante de pelo. Actas Dermosifiliogr. 2017;108:532–537.

\* Corresponding author.

E-mail address: [fjimenez@mediteknia.com](mailto:fjimenez@mediteknia.com) (F. Jiménez-Acosta).

## Introduction

Seven years ago in this journal, we published a review of the technique for hair transplant using follicular units (FU).<sup>1</sup> Although the basic concepts of hair transplant regarding the design of the frontal hairline and implantation in the receptor zones described in that review are still applicable, very significant changes have occurred in the method of extraction of the FUs from the donor area (known as follicular unit extraction [FUE]), which justify this update.

These days, the majority of transplant surgeons use 2 techniques indistinctly, the classic strip technique, also known as follicular unit transplant (FUT) or strip harvesting, and the FUE technique, though popularity of the FUE technique and patient demand has increased as it is a much less invasive method and this is perceived by the patient.

In this update we describe the general features of the FUE technique and its advantages, disadvantages, and controversies.

## Concept of Follicular Unit Extraction

FUE is an FU transplant technique in which extraction of the FUs from the donor area is performed using a punch with a diameter of approximately 1 mm. In the FUT technique, the FUs are harvested from a surgically excised strip of skin using a stereomicroscope whereas, in the FUE technique, FU extraction is performed blind, directly from the donor area, using a cylindrical punch, guided only by the direction of the hair shafts as they emerge through the skin surface. It must therefore first be understood that FUE differs from FUT only in the method of FU extraction; the implantation process in the recipient area is identical in the 2 methods.

FUE is similar to the punch grafting technique described by Okuda<sup>2,3</sup> in 1939 and Orentreich<sup>4</sup> in 1959, the main difference being the size of the punch used for the extraction. Whilst Okuda used punches of 2.5 to 3 mm and Orentreich punches of 4 mm (containing 10 to 20 hairs per punch), the ones in FUE are much smaller, because the aim is to extract only FUs (1 to 4 hairs per punch).

The first article on FUE was published in 2002 by Rassman et al.<sup>5</sup> In its early years, the technique was not widely adopted by transplant surgeons, mainly because of the difficulty of extracting intact FUs with such a small-diameter punch. However, over the past decade, after its challenging initiation in which few surgeons believed it would become established as an alternative to the strip technique, FUE has grown in popularity. There are several reasons for this: increased patient demand; improved surgeon proficiency in the extractions, acquired through greater experience and the availability of better instruments; results that, in the hands of experienced surgeons, are comparable to those of the strip technique; and greater interest of physicians new to this field to learn the technique, as FUE is a method that does not require microscopy or technicians trained in graft dissection.<sup>6</sup>

## Instruments Employed in Follicular Unit Extraction

The FU extraction process using the FUE technique involves 2 actions: the circular incision with the punch around the FU to

**Table 1** Follicular Unit Extraction Instruments.

### Punches

#### Sharp punches

- Titanium ([www.mediquipsurgical.com](http://www.mediquipsurgical.com))
- Cole serrated punch ([www.coleinstruments.com](http://www.coleinstruments.com))
- Ertip punch (Turkish) ([www.ertipmedical.com](http://www.ertipmedical.com))
- Ring punch (Dr. Roberto Trivellini)

#### Blunt punches

- Hex punch (flat tip) ([www.harrisfueinstruments.com](http://www.harrisfueinstruments.com))

#### Hybrid punches

- Hybrid trumpet punch ([www.devroyeinstruments.com](http://www.devroyeinstruments.com))

### Motorized devices

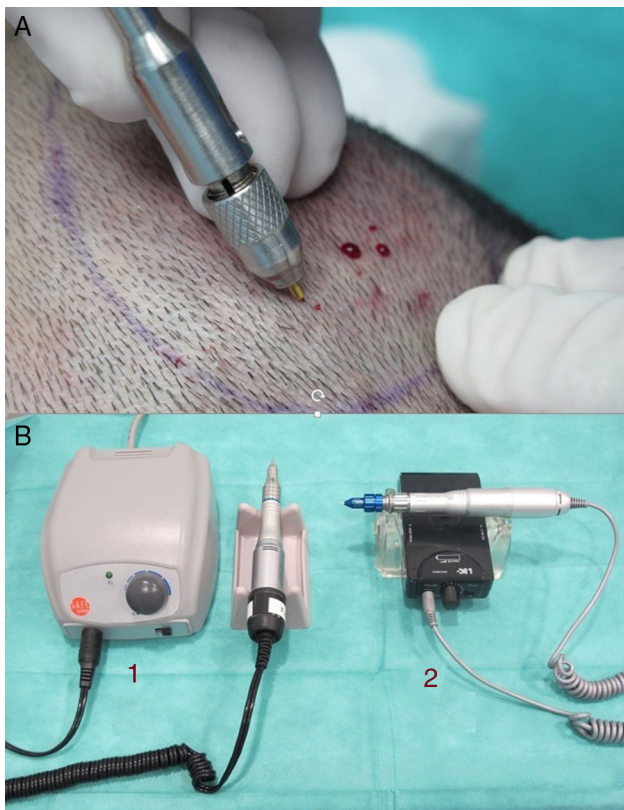
- SAFE System ([www.harrisfueinstruments.com](http://www.harrisfueinstruments.com))
- CDD-Vortex and PCID ([www.coleinstruments.com](http://www.coleinstruments.com))
- WAW system ([www.devroyeinstruments.com](http://www.devroyeinstruments.com))
- Mamba (Dr. Roberto Trivellini)
- Ertip FUE micromotor ([www.ertipmedical.com](http://www.ertipmedical.com))
- Dr. Jack's E-FUE device ([Robbinsinstruments.com](http://Robbinsinstruments.com))
- 4D FUE ([folliculartech.com](http://folliculartech.com))
- Smartgraft
- Neograft

liberate it from the adjacent dermal tissue; and extraction of the FU, usually performed with forceps.

The circular incision with the punch is the most difficult and delicate part of the extraction. The first instrument used to perform the incisions in FUE was the traditional 1-mm skin biopsy punch. The problem was that the only guide available to the surgeon to direct the punch was the angle of the hair as it emerged through the skin. The punch must cut around the whole FU, which is formed of follicles 4 to 5 mm deep. As the FUs are not rigid structures but can subtly change angle, irreversible damage due to follicle transection was very common. Because of this, early attempts were made to extract the FUs using larger punches (1.25 mm, 1.5 mm, and up to 2 mm), but this forfeited the concept of natural and undetectable FU transplant and furthermore, the scars left by the punches in the donor area were larger and were visible. Today, FU extraction using the FUE technique is performed with punches between 0.8 and 1.15 mm in diameter, the most widely used being 0.9 mm.

Instruments used in FUE can be divided into 3 types: manual (Fig. 1A), motorized (Fig. 1B), and the robotic arm (Table 1). With the manual system, the surgeon introduces the tip of the punch by hand and makes the incision around the follicular unit. With the motorized systems, the punch is introduced into a handpiece held by the surgeon and attached to a motor that rotates or oscillates the head of the punch at a given number of revolutions. With the robotic system, the surgeon selects the UF to be extracted on a screen and the robotic arm makes the circular incision around the unit. The Artas System (Restoration Robotics, San Jose, California, US) is the only robot manufactured and marketed exclusively for FUE.<sup>7,8</sup>

A wide variety of punches are available commercially, differing in the design of the punch tip. They are classified into sharp punches, blunt punches, and hybrid punches (Table 1). Sharp punches have greater cutting ability, while the blunt and hybrid punches are better for tissue dissection.<sup>9-11</sup> The extraction technique varies according to the type of punch



**Figure 1** FUE systems.

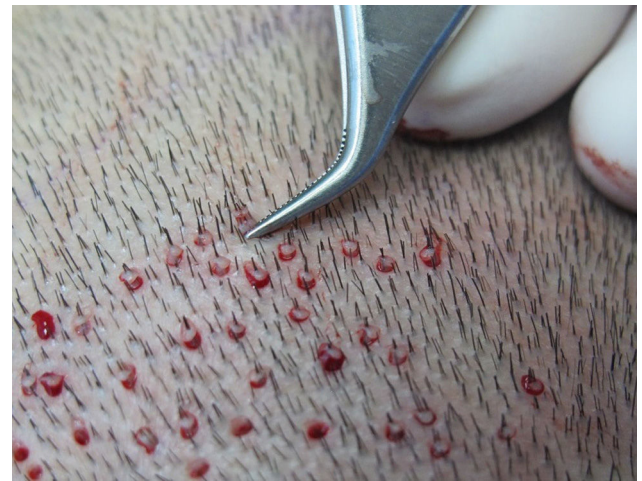A, Manual punch. Extraction of the follicular unit requires alignment of the punch with the angle and direction of emergence of the hair shaft, which must be kept in the center of the punch. B, Two motorized systems: the SAFE device by Harris (HSC Development, Colorado, US) (1) and the Vortex device by Cole (Cole Instruments, Georgia, US) (2).

employed, as we explain in the following section. In the coming years, new punches will appear on the market, designed to facilitate extraction of the FU and reduce the percentage of transected follicles to minimum acceptable levels, similar to those of the strip method (less than 5% to 10%). The Artas system uses a blunt punch that slides within a sharp punch.

In the authors' opinion, the instruments are very important, but so is the surgeon's experience and expertise. There are surgeons who only use manual sharp punches and achieve results as good as surgeons who use motorized systems with blunt or hybrid punches. Results thus depend not only on the type of instrument but also on the surgeon.

### Correct Extraction of Follicular Units Using Follicular Unit Extraction

To extract FUs with FUE, the punch must be aligned with the direction of emergence of the hair shaft, which must remain in the center of the punch (Fig. 2). The use of high-power magnification glasses (4-5x) is important because they make greater precision possible in the extraction. With modern punches, the hair must be cut to a length of 1 to 2 mm to see the angle of emergence; however, new punches not



**Figure 2** Incisions made with the punch around the follicular unit, with the hair in the center of the surface of the punch sections.

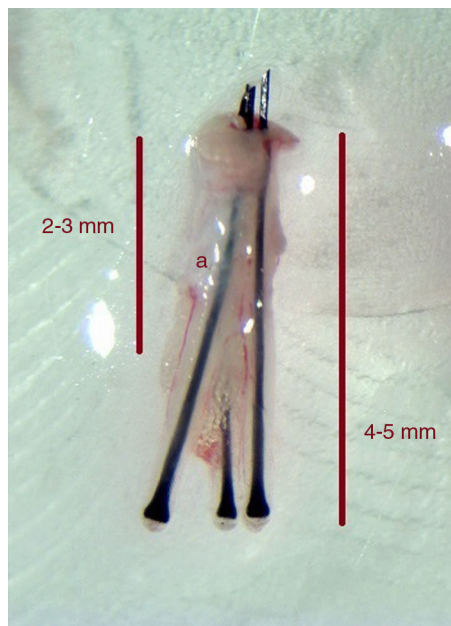
yet available commercially are being developed to permit extractions with long hair. The angle of emergence of the hair changes depending on the area of extraction. The hair emerges at a more acute angle in the temporal region and at the borders of the scalp. One of the recommended techniques to make the follicle adopt a more vertical position and thus facilitate extraction is to inject saline solution (tumescence) immediately prior to incision with the punch.<sup>12</sup>

The depth to which the punch should be introduced varies depending on whether a sharp, blunt, or hybrid punch is being used. Sharp punches are usually introduced to a depth of 2.5 to 3 mm; deeper than this (below the level of insertion of the arrector pili muscle), the deeper segments of follicles in anagen diverge, increasing the risk of transection (Figs. 3 and 4). Blunt and hybrid punches, because of their greater dissecting and lesser cutting effects, can be introduced deeper (>4 mm) with less risk of transection. However, blunt punches have a higher risk of pushing the graft into the dermis (buried grafts).<sup>10</sup>

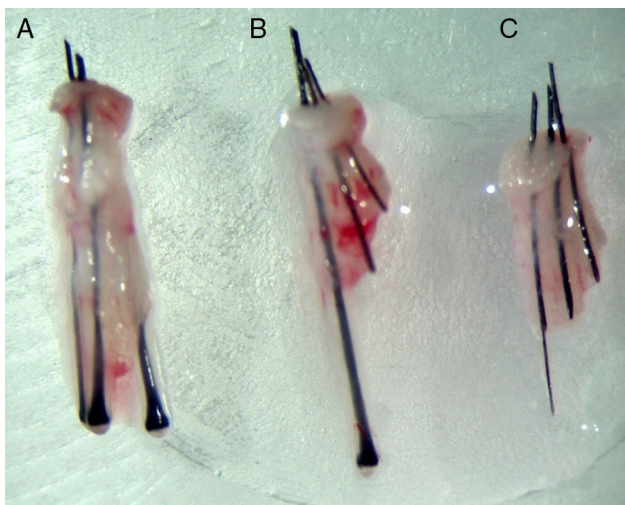
### Advantages and Disadvantages of Follicular Unit Extraction

One of the novelties of FUE has been the possibility to extract FUs from other body areas. This is useful in patients in whom the donor area of the scalp has a low density of FUs, as often occurs in patients who have undergone a number of previous transplants. The area of body hair most commonly used is the beard, especially the submandibular region (Fig. 5). Other areas from which follicles can be extracted are the chest, abdomen, pubis, legs, and axillas (Table 2).<sup>13,14</sup>

One undeniable disadvantage of FUE is that the procedure is very laborious and demanding on the surgeon. Depending on the surgeon's expertise, it can take 1.5 to 3 hours to obtain 1000 grafts using FUE, making this a very surgeon-dependent technique. Most surgeons limit sessions of FUE to a maximum of 1500 to 2000 FUs per day so as not to excessively prolong operating times.<sup>15</sup> In the experience of



**Figure 3** Punches with a sharp tip should only be introduced to a depth of 2 to 3 mm to minimize the risk of follicle transection. Blunt and hybrid punches can be introduced to a greater depth (> 4 mm)  
 a: Sebaceous gland.

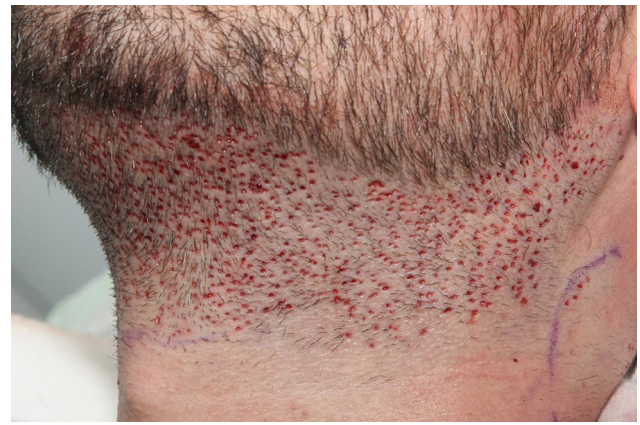

**Figure 4** Follicular units.  
 A, Normal, undamaged. B, Partial transection of 2 follicles. C, Complete transection of the follicular unit.

the authors, when 2000 or more FUs need to be extracted, it is preferable to do this on 2 consecutive days not only to limit operating times but also to minimize potential damage to the grafts.

### Choosing Between Follicular Unit Extraction and the Strip Technique

Almost any patient who is a candidate for strip transplant can also be a candidate for the FUE procedure (Fig. 6). However, there are situations in which the choice between



**Figure 5** Beard as the donor area; 1100 extractions performed using the sharp 0.9-mm Cole punch in the Vortex® motorized system (Cole Instruments, Georgia, US).

**Table 2** Advantages and Disadvantages of the Follicular Unit Extraction Technique.

#### *Advantages of Follicular Unit Extraction*

- Reduction of postoperative discomfort and of donor area healing time
- Almost imperceptible pinpoint scars

#### *Disadvantages of Follicular Unit Extraction*

- Slower, more laborious technique that is more demanding on the surgeon
- Requires shaving of the donor area before performing extractions
- Finer and more delicate follicular units (higher risk of damage during implantation)

**Table 3** Preferences for Use of Follicular Unit Extraction or the Strip Technique.

#### *Preference for Follicular Unit Extraction*

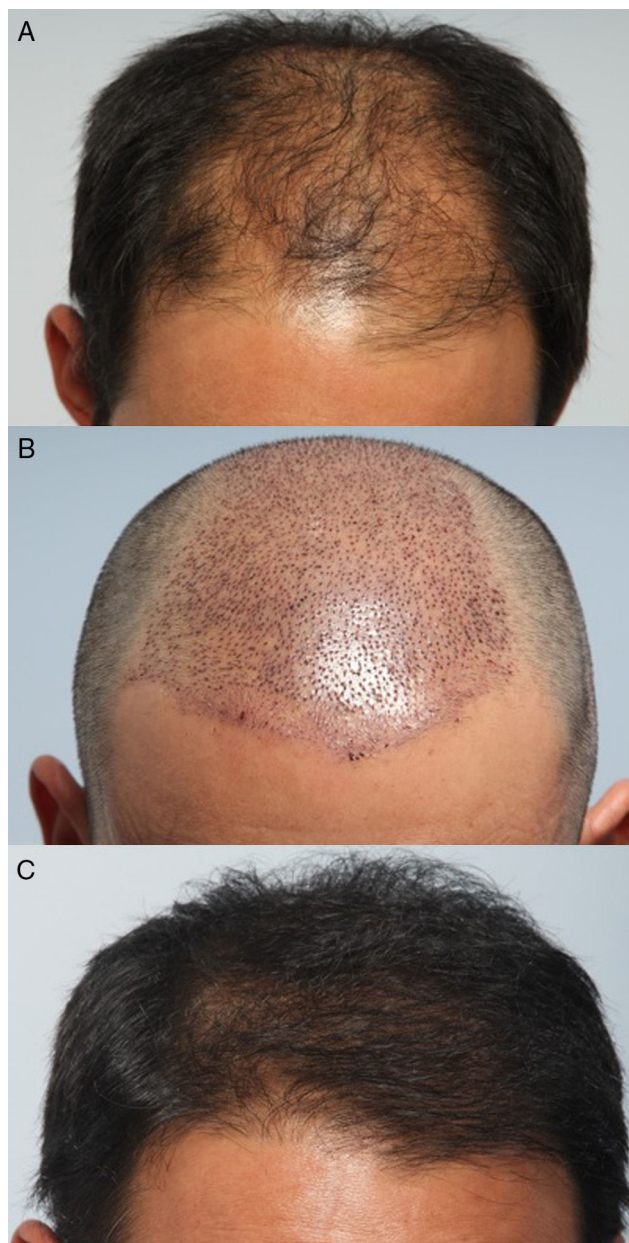- Patients with very short hair
- Young patients with a small recipient area
- Patients with considerable tension in the scalp skin
- Correction of scars from a previous transplant performed using the strip technique

#### *Preference for the strip technique*

- Sessions of more than 2500 follicular units in a single day
- Patients who do not want to shave their hair for the operation

techniques can be important (Table 3). For example, in young patients with small recipient areas, FUE gives much more freedom to cut the hair very short in the future and also allows additional sessions to be performed, when necessary, without obliging the patient wear long hair to cover the linear scar of the strip. However, patients who do not wish to cut their hair very short for the operation prefer the strip technique, as the linear scar will be covered by the remaining hair.

FUE is also indicated particularly when scars from a previous strip transplant cause tension in the scalp skin. Additionally, FUE is very useful to correct hypertrophic

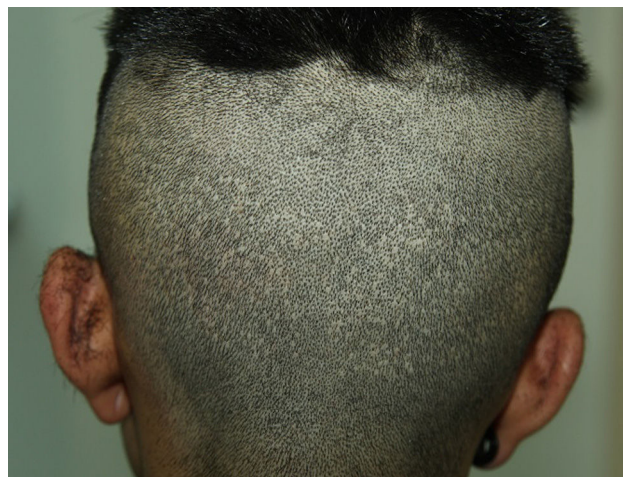

**Figure 6** Good candidate patient for either follicular unit extraction (FUE) or the strip technique. This patient received 2000 transplanted follicular units using the FUE method with the sharp 0.95-mm Cole punch in the Vortex system (Cole Instruments, Georgia, US).  
 A, Before transplant.  
 B, Twenty-four hours after follicular unit extraction.  
 C, Result a year after the intervention.

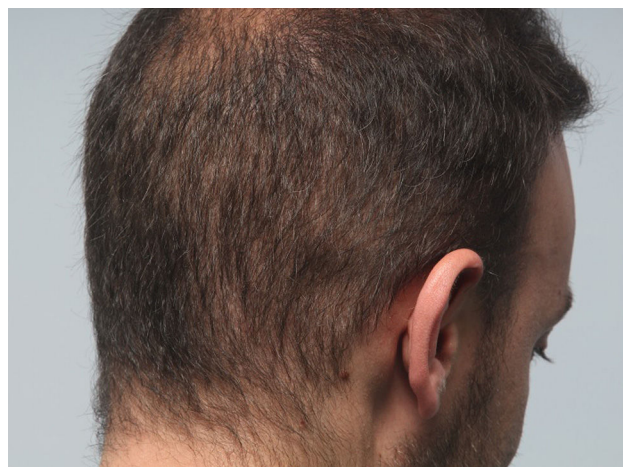scars from a previous transplant performed using the strip technique.<sup>16</sup>

### Controversies in Follicular Unit Extraction

Many patients have the mistaken idea that the FUE technique does not leave scars, as has been stated on some websites and internet blogs. This is not the case. Any extraction performed with a punch, however small, will leave a



**Figure 7** Hypopigmented pinpoint scars in the donor area of a patient who underwent follicular unit extraction with a blunt 0.9-mm punch (Harris SAFE system, HSC Development, Colorado, US).



**Figure 8** Excessive number of extractions causing thinning of the hair in the donor area leading to a moth-eaten appearance.

pinpoint scar. These scars are usually very hard to see, even with very short hair, but this is not necessarily the case in all patients (Fig. 7). One of the most debated aspects of FUE is damage to the donor area when a very large number of extractions are performed. In other words, what is the maximum number of extractions that can be taken from the donor area without the damage becoming clinically visible? In theory, taking into account that most individuals have an FU density between 70 and 80 FUs per square centimeter and that up to 15 to 20 FUs per square centimeter can be extracted in each session, it is estimated that the maximum recommended limit is of approximately 3000 to 4000 FU extractions per session.<sup>15</sup> However, after several sessions of FUE, each one with thousands of extractions, the donor area can be left with a very low hair density and acquire a moth-eaten appearance (Fig. 8). It is also important to perform the extractions uniformly across the whole donor area, so as not to leave some areas with a lower density than others.

Finally, some experts still doubt that growth of the FUE grafts is the same as is achieved with the strip technique.<sup>17</sup>

The controversy arises because FUs extracted using FUE are typically smaller (skeletonized), while those dissected by microscopy are thicker and include more of the surrounding adipose tissue. Perhaps the poor growth observed in some cases of FUE occurs because the smaller FUs require more delicate handling during implantation, as there is a higher risk of damaging the hair bulbs and dermal papillas, the most sensitive part of the follicle. Controlled studies comparing graft survival after extraction using each technique need to be performed to resolve this controversy.

## How to Learn and Start to Practice FUE

The appearance of FUE has led to increased interest in learning hair transplant techniques. However, FUE has a long learning curve and sufficient knowledge cannot be acquired in a weekend workshop. Furthermore, as there is a significant delay until results are seen (between 6 and 12 months), surgeons can take a long time, sometimes years, to develop the competence required for this procedure and to implement appropriate quality controls.

One of the best ways to learn FUE is to attend the annual workshops and conferences organized by the International Society of Hair Restoration Surgery ([www.ISHRS.org](http://www.ISHRS.org)). This Society also offers 1- or 2-year fellowships in a number of accredited clinics.

## Conclusions

Ideally the transplant surgeon should know and be able to perform the 2 techniques (FUE and strip) to be able to use the most appropriate one for each patient and not the most convenient one for the surgeon.

The most interesting advantages of FUE compared to FUT are the reduction in postoperative discomfort in the donor area and the lower visibility of the pinpoint scars. The main disadvantages of FUE are that it is more laborious, leading to longer operating times, and its long learning curve.

## Conflicts of Interest

The authors declare that they have no conflicts of interest

## References

1. Jimenez F, Ponce I. Técnica actual del trasplante de pelo de unidades foliculares. *Actas Dermosifiliogr.* 2010;101:291–306.
2. Okuda S. Clinical and experimental studies of transplantation of living hairs. *Jpn J Dermatol Urol.* 1939;46:135–8.
3. Jimenez F, Shiell RC. The Okuda Papers: An extraordinary –but unfortunately unrecognized– piece of work that could have changed the history of hair transplantation. *Exp Dermatol.* 2015;24:185–6.
4. Orentreich N. Autografts in alopecias and other selected dermatologic conditions. *Ann NY Acad Sci.* 1959;83:463–79.
5. Rassman WR, Bernstein RM, McClellan R, Jones R, Worton E, Uyttendaele H. Follicular unit extraction: Minimally invasive surgery for hair transplantation. *Dermatol Surg.* 2002;28:720–8.
6. Rassman W, Pak J, Kim J. Follicular unit extraction: Evolution of a technology. *J Transplant Technol Res.* 2016;6:158.
7. Avram MR, Watkins SA. Robotic follicular unit extraction in hair transplantation. *Dermatol Surg.* 2014;40:1319–27.
8. Bernstein RM, Wolfeld MB. Robotic follicular unit graft selection. *Dematol Surg.* 2016;42:710–4.
9. Cole J. An analysis of follicular punches, mechanics, and dynamics in follicular unit extraction. *Facial Plast Surg Clin North Amer.* 2013;21:437–47.
10. Harris JA. The SAFE system: New instrumentation and methodology to improve follicular unit extraction (FUE). *Hair Transplant Forum Int.* 2004;14:157.
11. Devroye J. Powered FUE extraction with the short arc oscillation flat punch FUE system (SFFS). *Hair Transplant Forum Int.* 2016;26:34–6.
12. Zontos G, Rose PT, Nikiforidis G. A mathematical proof of how the outgrowth angle of hair follicles influences the injury to the donor area in FUE harvesting. *Dermatol Surg.* 2014;40:1147–50.
13. Umar S. The transplanted hairline: Leg room for improvement. *Arch Dermatol.* 2012;148:239–42.
14. Umar S. Body hair transplant by follicular unit extraction: My experience with 122 patients. *Aesthetic Surg J.* 2016;36:1101–10.
15. Ors S, Ozkose M, Ors S. Follicular unit extraction hair transplantation with micromotor: Eight years experience. *Aesthetic Plast Surg.* 2015;39:589–96.
16. Harris JA. Follicular unit extraction. *Facial Plast Surg Clin North Am.* 2013;21:375–84.
17. Beehner ML. FUE vs FUT-MD: Study of 1,780 follicles in four patients. *Hair Transplant Forum Int.* 2016;26:160–1.